

Recurrent Transverse Vaginal Septum Presenting as Lactational Amenorrhea: A Rare Presentation of a Rare Anomaly

Supriya Dankher^{1*}, Vandana Chandraul², Sanjeev Guru² and Pancham Preet Kaur³

¹Head, Department of Obstetrics and Gynaecology, ESIC Hospital Sahibabad, India

²Chief Medical Officer, Department of Obstetrics and Gynaecology, ESIC Hospital Sahibabad, India

³Assistant Professor, Department of Obstetrics and Gynaecology, VMMC and Safdarjung Hospital, New Delhi, India

*Corresponding author: Supriya Dankher, Head, Department of Obstetrics and Gynaecology, ESIC Hospital Sahibabad, India; E-mail: supsdhankher@gmail.com

Received: March 22, 2025; Accepted: April 23, 2025; Published: May 03, 2025

Abstract

Introduction: Transverse vaginal septum is a rare congenital Mullerian duct developmental anomaly with varied presentations in different age groups. Depending on its location in vagina, it can be a high, middle or low transverse vaginal septum, thus causing hematometra with or without hematocolpos. Diagnosis of transverse vaginal septum in female with symptoms of obstructive vaginal pathology is usually made with a careful gynaecological examination and USG. MRI may also be considered particularly in women with recurrence to know septal thickness and any distortion in anatomy from previous surgery.

Case Report: We report case of a 22-year-old lactating mother presenting as lactation amenorrhea and lower abdominal pain. She was diagnosed as a case of recurrent low transverse vaginal septum with hematocolpos and hematometra. She underwent Y-V plasty with drainage of hematometra and hematocolpos with mould with drainage placement. On follow up she resumed her menses and able to cohabit normally after 3 months of surgery.

Conclusion: In females with primary amenorrhea, differentiating imperforate hymen and transverse vaginal septum is important. Transverse vaginal septum is known for its high rate of recurrences after surgery and will require postop dilators and regular postop follow up. Using Mould with drainage is suggested for allowing longer intervals for mould change particularly in patients with hematometra and hematosalpinx.

Keywords: *Transverse vaginal septum; Secondary amenorrhea; Lactational amenorrhea; Vaginal mould with drainage; Imperforate hymen; Mullerian anomaly*

Citation: Dankher S, Chandraul V, Guru S, et al. Recurrent Transverse Vaginal Septum Presenting as Lactational Amenorrhea: A Rare Presentation of a Rare Anomaly. 2025;8(2):338.

©2025 Yumed Text.

1. Introduction

Transverse vaginal septum is a rare congenital Mullerian duct developmental anomaly. The incidence of transverse vaginal septum varies from 1:40000 to 1: 84000. Histologically a septum is a fibrotic tissue with muscular and vascular components of varying thickness. The clinical presentation, anatomic location and fertility outcome of a vaginal septum are highly variable. The transverse vaginal septum can be perforated and imperforated. Woman with imperforated vaginal septum presents usually in the neonatal period or early puberty. During the neonatal period, it presents as hydrometrocolpos due to the accumulation of vaginal secretions, while in teenage she comes with primary amenorrhea with cyclical pain as a feature of obstruction in menstrual flow. Women with perforated transverse vaginal septum usually have a normal menstrual cycle and present as primary infertility, dysmenorrhoea, dyspareunia, and issues with childbirth usually after starting sexual life [1,2].

The etiology of vaginal septa is unknown but may be multifactorial in origin, due to exposure to agents in utero, or associated with autosomal recessive inheritance [3].

We present a rare case of lactating female with five months old infant with complaints of amenorrhea and pain abdomen. As per our literature search this is the first case of transverse vaginal septum which was diagnosed in a lactating female.

2. Case Presentation

A 22 years old married lactating female with 5 months old infant presents to our OPD with complaints of amenorrhea since childbirth and pain lower abdomen which persistent and dull aching. She is P1L1 with one child born via lower segment caesarean section 5 months back. She is exclusively breast feeding her child at the time of presentation.

As it seems to be a case of lactational amenorrhea and she was counselled for same on which she gave history of some vaginal surgery to dilate narrow vagina before conception. On further elaborate history taking she gave history of some other vaginal surgery in view of primary amenorrhea at 14 years of age. On examination of her surgical records, she was operated for imperforate hymen and during surgery a needle was placed and dissection was done around needle and an opening was created following which collected blood was expelled out. No examination was mentioned on surgical record to differentiate imperforate hymen and distal transverse vaginal septum. She was advised for vaginal dilatation in postop period which she failed to do for long. After this procedure she resumed her menses which were normal as per her.

After marriage at the age of 20 years, she had complaints of dyspareunia for which she approached another doctor and on examination a small vagina was seen. She underwent an examination under anesthesia, but no definitive septum was seen and mucoid discharge seems coming out from anterior vagina and this opening was dilated and dilators were advised. Following this she conceived within 3 months. Her pregnancy was uneventful and as per her surgical records she had elective LSCS in view of postdated pregnancy (41 weeks) short stature and free-floating head considering cephalopelvic disproportion, her PV examination was not mentioned. Intraoperatively, uterus and adnexa are normal in morphology and liquor was MSL Grade 2. She had no bleeding in postpartum phase, rest her postpartum period was uneventful. She did not had sexual intercourse after LSCS till the time of presentation.

Once she approached our OPD with complaints of amenorrhea and pain lower abdomen, after this history taking, she was examined. On per abdomen, uterus was enlarged 14 weeks gravid uterus size and tender to touch. On local examination, a blind vaginal pouch was seen around 1.5 cm in length with a shallow dimple without any bulge and per vaginal examination could not be done in view of very short vagina (FIG. 2). On USG, uterus was dilated with around 50 cc of fluid? hematometra /pyometra, also a tubular dilated structure was seen in left adnexa? hematosalpinx. On MRI without contrast, hematometra 6.9*4.3*6.3 cm along with hematocolpos 9.1*6.5*8 cm and hematosalpinx {left 5.1*3.1 and right 2.1*0.9 cm} was reported. Cervix was also seen normal and dilated. Also, on MRI no definitive vaginal septum was seen but sudden tapering of vagina was present with hematocolpos above it (FIG. 1). Kidneys and ureters were normal on MRI. Considering all these examination and investigations, provisional diagnosis of recurrent transverse vaginal septum in distal vagina was made and Y-V plasty and drainage of hematometra and hematocolpos with mould (with drainage) placement was done under saddle block (FIG. 3). Around 500 ml of blood was drained. She did well in postop period and discharged on postop day 3 after mould change. She came visiting to us alternative day for mould change and after 3 weeks she was able to do it by herself without inconvenience. Her postoperative USG on day 21 showed normal uterus and adnexa and complete resolution of hematometra and hematosalpinx. She resumed her menses and able to cohabitately normally 3 months after surgery.

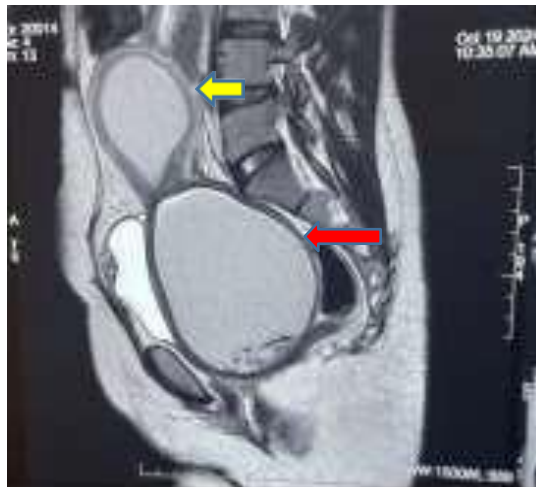


FIG. 1. MRI picture showing hematometra (yellow arrow) and hematocolpos (red arrow).

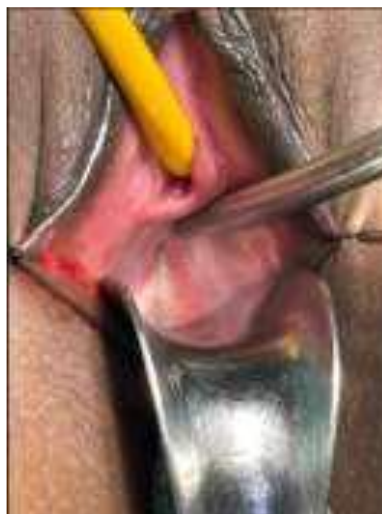

FIG. 2. Preoperative image showing blind small vaginal pouch with central dimple pointed by Hegars dilator.

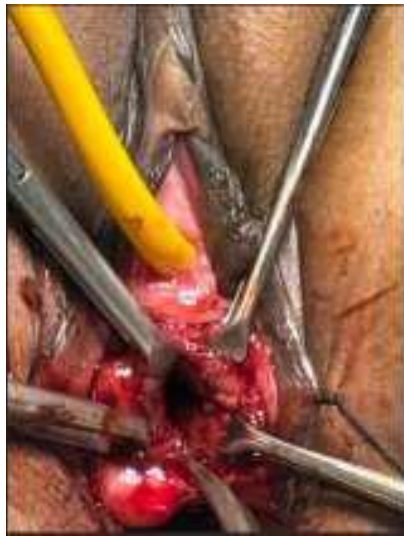

FIG. 3. Examination before Surgery.

3. Discussion

An obstructive vaginal anomaly causing hematometra and hematocolpos can be an imperforate hymen or transverse vaginal septum. Theoretically, an imperforate hymen can be easily distinguished from a transverse vaginal septum on physical examination. The bluish appearance with a bulge is often observed between the two labia minora in the case of an imperforated hymen. In addition, slight pressure applied suprapubically causes visible distension of the imperforated hymen. On the other hand, if a transverse septum is present, suprapubic pressure does not cause a visible bulge in the perineum. Both these findings will not be there in transverse vaginal septum [4].

For imperforate hymen, surgical hymenectomy is the standard treatment and can be done with X, T, cross or cruciate incision with resection of excess tissues but sometimes even a vertical incision of hymen may resolve the problem [1-6]. Fortunately, almost all patients will cure permanently with standard surgery with only one reported exception [7]. However transverse vaginal septum is known for its recurrences after surgery.

In our case, patient underwent surgery during her teenage with diagnosis of “Imperforate hymen” and surgery mentioned as “Hymenectomy”. As no intraoperative notes were mentioned in her past surgical records, we cannot comment upon what exactly was done, but it seems to be a low transverse vaginal septum which was wrongly diagnosed as imperforate hymen. Our first learning from this case is that although distinction of imperforate hymen and transverse vaginal septum seems quite easy once reading it, it can be challenging clinically due to rarity of these cases particularly in low transverse vaginal septum, as in our case.

Also, this differentiation is crucial, as surgery, for these two conditions is quite different i.e., simple incision on bulging imperforate hymen with excision of any excess tissue is enough. Only rare recurrences are reported post-surgery in imperforate hymen and it doesn't require any postop vaginal dilators. On contrary, for transverse vaginal septum various surgical alternatives, including the vaginal approach, a combined abdominoperineal approach, and laparoscopic resection from the abdominal route were published. Surgical technique will depend on the location, thickness of the septum, and operator skills

[6]. Even now, very little data is available in the literature on the surgical management of TVS and surgical management guidelines are still up for debate. Also, various surgeries of the transverse septum of the vagina, despite their complexity, are complicated by vaginal stenosis and recurrences (TABLE 1).

TABLE 1. Summary of various related case reports for discussion.

	Case 1	Case 2	Case 3	Case 3
Case report	Pipal et al, 2023 ^[5]	Kamal et al, 2020 ^[4]	Priyatini et al, 2022 ^[2]	Barut et al, 2022 ^[6]
Age at presentation	15 years	16 yrs	13 yrs	14 yrs
Chief complaints	Primary amenorrhea with persistent pain lower abdomen preceded by cyclical pain	Primary amenorrhea with cyclical pain abdomen	Primary amenorrhea with cyclical abdominal pain	Severe pelvic pain with primary amenorrhea
Associated comorbidities	No	Congenital right kidney agenesis	No	No
Duration of complaints	1 year		Several months	Several months
Previous surgery for TVS	No	No	No	Yes, septum excision 2 months earlier
Secondary sexual characters	Well developed	Normal	Normal	Well developed
Septum location	Lower 1/3 rd of vagina	Lower 1/3 rd of vagina	2 cm from hymen	2 cm from hymen
Septal thickness	Not mentioned	1 cm	8.7mm	Not mentioned
Vaginal length	Not mentioned	1 cm	2 cm	2 cm
Hematocolpos	Yes	Yes, 10*12 cm	Yes	Yes
Associated mullerian anomalies	Distal vaginal atresia	No	No	No
Surgical technique used	TVS resection and edges sutured to hymenal ring with pull through vaginoplasty	Circumferential TVS excision and tarring of entire circumference with vicryl 20 and placement	Interdigitating “Y-flap” surgery	Cicumferential incision with end-to-end vaginal anastomosis with Intravaginal foleys catheter and estrogen cream for

	and mould placement	of Estrogen soaked sponge		3 months
Recurrence in post up	Not mentioned	No	No	No
Postop dilators used	Yes	No	No	No
Postop evaluation	Duration not mentioned	Within normal limits till 2 years postop follow up	10 cm vaginal length at 1-month follow up	Normal menstruation after 6 months without recurrence

After surgery in transverse vaginal septum, vaginal mould/ stent/ foleys placement is reported in literature for prevention of restenosis of raw vaginal areas till patient is able to perform self vaginal dilatation using dilators or is sexually active. Self-use of dilators is usually troublesome as these patients are mostly teenagers, are not sexually active and experiencing postoperative pain too.

Moulds used in postoperative period are commonly made with syringe or sponge or with a combination of both. In our case, as patient had significant hematometra and hematosalpinx along with hematoocolpos, we used a mould with drainage for gradual drainage of collected blood and debris, as we kept mould placed intraoperatively for 3 days in postoperative period before changing it. Mould we used to be made with a 20 cc syringe (plunger removed) with its anterior nozzle and cover being cut to make an opening to accommodate rubber drain of good calibre (28 FG abdominal drain). Drain was placed through this opening made, following this, a foam approx. 1.5 cm thickness (squeezeable) was wrapped over syringe (covering both ends of syringe) and fixed with suture. Then two condoms were placed over this and tied with suture to rubber drain at both anterior and posterior ends. Condom tip covering anterior end of drain was incised and condom was retracted to ensure free drainage through patent holes (FIG. 4).

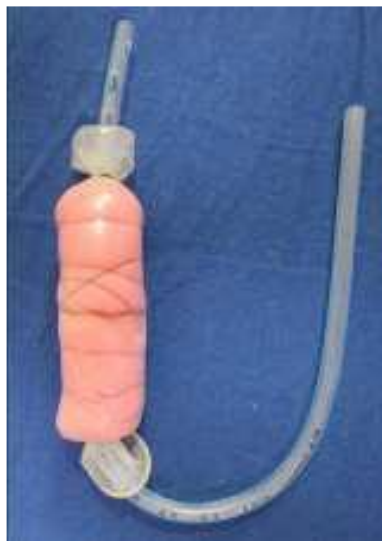

FIG. 4. Mould with drain.

This kind of mould with drainage gives us an additional advantage for keeping mould for long durations before initial change till patient become more comfortable in postop period. This kind of mould is also cost effective and ensure continuous drainage of collected hematometra and hematosalpinx.

4. Conclusion

Transverse vaginal septum is a rare anomaly of female genital tract which presents in different age group females with varied presentations. In females with primary amenorrhea, differentiating it from imperforate hymen is important. As transverse vaginal septum is known for its high rate of recurrences after surgery and will require postop dilators and regular postop followup. Mould placement and changing it on intervals till, patient is able to perform vaginal dilation by self is also needed with various surgical techniques. We suggest using Mould with drainage for allowing longer intervals for mould change particularly in patients with hematometra and hematosalpinx.

5. Acknowledgements

None.

6. Authorship Contribution Statement

Author 1: Conceptualization, data curation, formal analysis, investigation, writing- original draft. Author 2: Investigation, formal analysis. Author 3: Resources involved, methodology. Author 4: Writing - review and editing.

7. Conflict of Interest

Authors have no conflict of interest.

8. Funding

No funding from any source.

REFERENCES

1. Yadav G, Agrawal N, Binit S, et al. Transverse vaginal septum presenting as secondary amenorrhoea: a rare clinical presentation. *BMJ Case Rep.* 2020;13(8):e235374.
2. Priyatini T, Moegni F, Hidayah GN, et al. Case series: Interdigitating “Y” flap for transverse vaginal septum management. *Int J Surg Case Rep.* 2022;100:107601.
3. Gupta R, Bozzay DJ, Williams DL, et al. Management of Recurrent Stricture Formation after Transverse Vaginal Septum Excision. *Case Rep Obstet Gynaecol.* 2015;2015:975463.
4. Kamal EM, Lakhdar A, Baidada A. Management of a transverse vaginal septum complicated with hematocolpos in an adolescent girl. *Int J Surg Case Rep.* 2020;77:748-52.
5. Pipal VR, Seth S, Pipal DK. A rare case of hematometrocolpos due to transverse vaginal septum along with distal vaginal atresia in an adolescent girl. *J West Afr Coll Surg.* 2023;14(1):118-20.

6. Barut A, Hirs Z A, Yusuf K. Management of an isolated complete imperforate transverse vaginal septum: A case report. *Int J Surg Case Rep.* 2022;100:107744.
7. Ghadian A, Heidari F. Is Hymenotomy Enough for Treatment of Imperforated Hymen? *Nephro Urol Mon.* 2013;5(5):1012.