

Does MDCT Unravel the Hidden Domains of Conventional Radiography in Calcaneal Fractures?

Javaid Iqbal^{1*}, Moonisah Rafiq² and Abid Hussain³

¹Senior Resident (MD Radiodiagnosis and Imaging) Government Medical College Srinagar J&K, India

²MD Radiodiagnosis and Imaging, Sher-i-Kashmir Institute of Medical Sciences, SOURA Srinagar, J&K, India

³MS Orthopaedics, SKIMS Medical College, Bemina, Srinagar, J&K, India

*Corresponding author: Javaid Iqbal, Senior Resident (MD Radiodiagnosis and Imaging) Government Medical College Srinagar J&K, India, Tel: +91914995854/+919622380884; E-mail: drmalik91@gmail.com

Received: April 04, 2023; Accepted: April 27, 2023; Published: May 05, 2023

Abstract

Background: The most often fractured bone among the tarsal bones is the calcaneum. The first assessment of the suspected calcaneum fracture is conventional radiography. The modern assessment of calcaneal fractures is mainly based on multidetector computed tomography, because of its three-dimensional nature and Volume rendering techniques. The objective of this study was to compare the diagnostic value of Multidetector CT with Conventional radiography in Calcaneal fractures taking operative data as reference standard.

Materials and methods: We included 68 cases in our study, suspected of calcaneal fracture. The participants were further subjected to conventional radiography and computed tomographic imaging and results were compared. The Sensitivity, specificity and diagnostic accuracy were 92.6%, 33.33%, 82.3% and 98.3%, 71.4%, 95.5% for conventional radiography and MDCT respectively.

Conclusion: We settled that MDCT is far ahead of the conventional radiography in complete depiction, diagnosis, characterization and treatment formulation for calcaneal fractures.

Keywords: MDCT- Multidetector Computed Tomography; VRT- Volume Rendering Technique; PPV- Positive Predictive Value; NPV-Negative Predictive Value

1. Introduction

The Calcaneal fractures are the most common fractures among the tarsal bones, representing 60%-75% of all the tarsal fractures in adults and constitutes approximately 2% of all fractures [1]. These fractures are more common in younger age group

predominantly in males [2,3]. The first assessment of Calcaneal fractures depends on conventional radiography. The Calcaneal fractures are often identified on a lateral ankle radiograph. Additional views can be requested if required. The Bohler and Gissane angles are used to assess the severity of fractures.

Computed tomography is a modality of choice to evaluate Calcaneal fractures. It gives exact delineation of fracture and can depict with greater accuracy whether the fracture is intra-articular or extra-articular based on sub-talar joint involvement [4]. In addition to delineation, the cross-sectional imaging also helps to evaluate the other fractures and soft tissue and muscular injuries. Through MPR and VR reconstruction is possible to assess accurately the fracture lines, dislocation, crushing, the morphology and the involvement of the articular surfaces, allowing to choose appropriate treatment and have a better prognostic evaluation. Early diagnosis facilitates treatment of fracture thus reduces the long-term complications [5].

The aim of this study was to assess conventional radiography versus computed tomography for evaluation of Calcaneal fractures taking operative/MRI findings as gold standard.

2. Patients and Methods

This was a cross-sectional observational study conducted over a period of 2 years. This study included 68 patients with history of significant foot trauma. The cases included in the study were either diagnosed Calcaneal fractures on conventional radiography or having high clinical suspicion for Calcaneal fracture. Patients with severe medical ailments and unfit for surgery are excluded.

All patients were subjected to complete history taking, physical examination and digital radiographic examination and further Computed Tomographic assessment of traumatic foot.

All patients underwent the same MDCT protocol using 0.5 mm collimation, image thickness of 0.5 mm with tube voltage of 120 kV and 240 mAs. Images were carried in both bone window for fracture classification and soft tissue window for tendon entrapment and other soft tissue abnormalities. Sagittal, coronal and axial 2D and 3D MPR reconstruction were carried out.

Fracture classification: Classification of the fracture was done according to Sanders' as follows; Type I- Non displaced or displacement less than 2 mm. Type II- Fractures consisted of two articular pieces from a single intra-articular fracture line. Type III- Fractures consisted of three articular pieces from two fracture lines. Type IV- Comminuted fracture [6].

3. Statistical Analysis

The data was analyzed by the principal investigator with advice from a statistician. SPSS 23.0 (IBM, Armonk, NY, USA) was used for statistical analyses. With the surgical findings taken as the gold standard, the sensitivities, specificities, positive predictive values (PPVs), negative predictive values (NPVs), and diagnostic accuracies of Digital radiography and Computed tomography for the diagnostic evaluation of Calcaneal fractures were calculated. $P < 0.05$ was taken to indicate statistical significance.

4. Results

This study included 68 patients which were diagnosed with Calcaneal fracture. 40 were males (58.8%) and 28 females (41.1%) with mean age of 32 years. The associated injuries were soft tissue edema in 32 cases (47%), muscle injuries in 8 (11.7%) and tendon injuries in 5 cases (7.3%). 21 patients were presented with multiple fractures in other bones (35%). The extra articular Calcaneal fractures were present in 22 cases (32.3%) and intra articular fractures were noted in 48 cases (70.5%) (FIG. 1). The frequency and percentage according to sanders classification was more in type IV fracture. The Sensitivity, Specificity, positive predictive value, negative predictive value and diagnostic accuracy was 92.86%, 33.33%, 86.6%, 50%, 82.3% for digital radiograph and 98.3%, 71.4%, 96.77%, 83.33%, 95.59% for computed tomography respectively (FIG. 2&3). The sensitivity, specificity, PPV, NPV and diagnostic accuracy was far better in CT than digital X-ray in diagnostic evaluation, accurate depiction and treatment planning for Calcaneal fractures (TABLE 1-4).

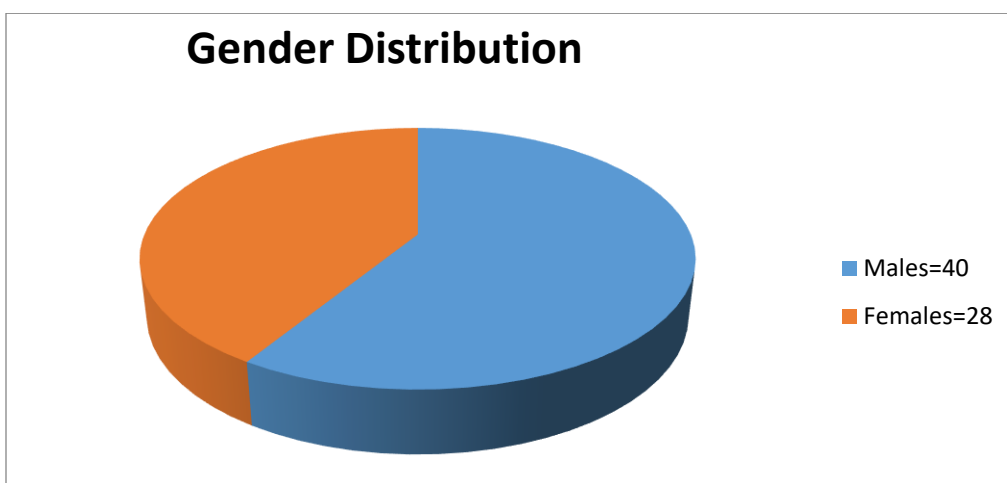


FIG. 1. Pie chart depicting the Gender distribution.

TABLE 1. Depicting the patient Characteristics.

Age (years)	Range	Mean+/- SD
	18-51yrs	36 +/- 7.6yrs
Gender:		
Male	Female	Total
40	28	68

Table 2. DEPICTS the associated injuries in Calcaneal fractures.

Soft tissue edema n (%)	32 (47%)
Muscle injuries n (%)	8 (11.7%)
Tendon injuries n (%)	5 (7.3%)
Associated fractures in other bones (%)	22 (32.3%)

TABLE 3. Reveals the Comparison of Digital Radiograph With Computed radiography in Calcaneal fractures taking operative/MRI findings as gold standard.

Conventional Radiography/Digital X-ray	True Positive	False positive	True negative	False negative	Total	Surgical (Reference Standard)
n=68	52	08	04	04	68	60
Computed Tomography						
n=68	60	02	05	01	68	60

TABLE 4. Depicts the sensitivity, specificity, PPV, NPV and diagnostic accuracy between Digital radiograph and CT.

Parameters	Digital Radiography	Computed Tomography
Sensitivity	92.86%	98.3%
Specificity	33.33%	71.4%
Positive predictive value	86.6%	96.77%
Negative Predictive Value	50%	83.33%
Diagnostic accuracy	82.3%	95.59%

5. Representative Case

38-year-lady presented with history of fall from height.

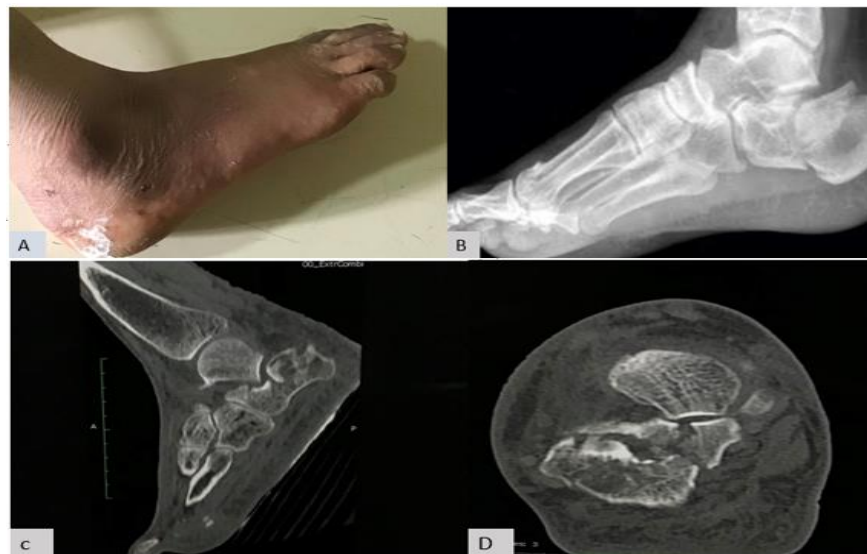

FIG. 2. A. Image depicting the Swelling of ankle. B. X-ray lateral view depicting the fracture of the Calcaneum. C/D. Saggital and Axial Images revealing the comminuted fracture of the Calcaneum with intra-articular extension.

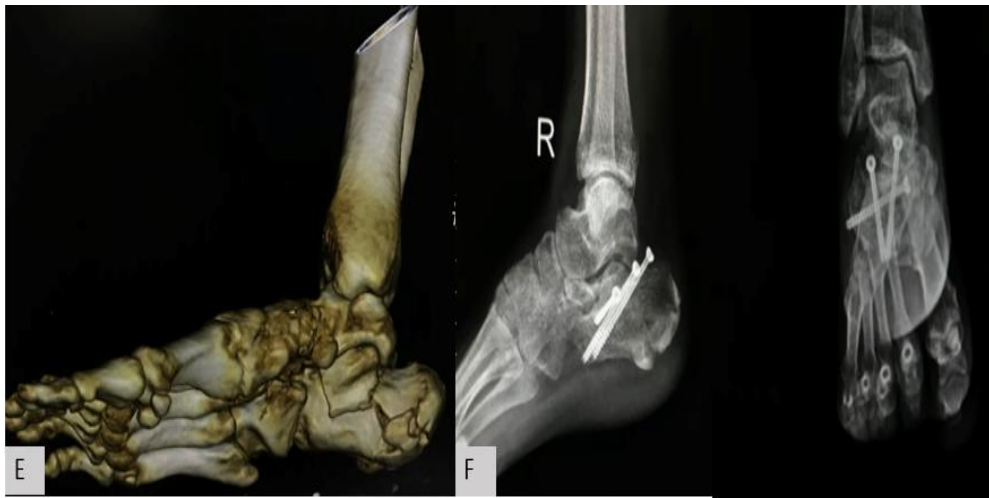

FIG. 3. E. 3-D VRT image revealing the comminuted nature of calcaneal fracture with intra-articular extension. F. Follow up post operative x-ray lateral and AP view of ankle showing well reduced fracture with metallic implants seen *insitu*.

6. Discussion

The prospective observational study revealed calcaneal fractures were the most common fractures among the tarsal bones. Our study revealed that calcaneal fractures were more common in young males than females and most common cause found was fall from height. These results were in concordance with the study done by Sanders RW et al [2] which found the similar results. The associated injuries in most patients were soft tissue edema, muscle injuries, tendon injuries and fractures in other bones. The majority of patients about 47% presented with associated soft tissue edema and 32.3% present with fractures in other bones as well, which were in concordance with the study done by W. Berberian et al. [7].

The intra articular calcaneal fractures were more common in our study than the extra articular and comprised 70.5% of calcaneal fractures. These results were in agreement with the study done by Miller MD et al. [8].

The frequency and percentage according to sanders classification was more in type IV fracture in our study and comprised 38% of the cases. while as, type I were the least. Similar results were established by Brunner et al. [9] who stated that type I was uncommon and other types from type II to type IV were nearly similar in their percentage of occurrence.

The Conventional radiograph reveals 92.8% sensitivity, 33.33% specificity, 86.6% ppv and 82.3% diagnostic accuracy. Zhang et al. [10] approved the sensitivity and specificity of about 94.85 and 79.09% respectively in calcaneal fractures. Madadi et al. [11] and vannier et al. [12] affirmed similar results.

The computed tomographic analysis of calcaneal fractures reveals the 98.3% sensitivity, 71.4% specificity, 96.7% ppv, 83.3%, npv and 95.59% diagnostic accuracy. Madadi et al. [12] agreed with us in considering CT as high specific modality for diagnosis and characterization of calcaneal fractures. Tanyu et al [13] shows concordance with our results and confirmed the enhanced diagnostic value of CT scan for calcaneal fractures. Thus, we find that sensitivity, specificity and diagnostic accuracy was far

better in Cross sectional imaging than conventional imaging in diagnosis, characterization, classification, treatment planning and indicator to determine the outcome of the treatment.

The development of multidetector CT has transformed CT from a simple cross sectional imaging technique to an advanced, three dimensional (3-D) imaging modality, enabling excellent 3-D displays. Its advantages over its predecessor, single-slice helical CT, are isotropic imaging capability and ease of interpretation.

7. Conclusion

CT imaging of calcaneal fracture is utmost important to unveil the hidden domains of conventional radiography, thus helping in exact delineation, characterization and helping in formulation of highly yielding treatment modality.

REFERENCES

1. Eiff MP, Hatch RL. Fracture management for primary care. 3rd ed. Philadelphia: Elsevier Saunders, USA; 2012.
2. Sanders RW, Clare MP. Calcaneous fractures. In: Bucholz RW, Heckman JD, Court Brown CM, Tornetta P, editors. Rockwood and Green's fractures in adults. 7th ed. Philadelphia: Lippincott Williams and Wilkins, USA; 2010. 2064 p.
3. Mitchell MJ, McKinley JC, Robinson CM. The epidemiology of calcaneal fractures. *Foot (Edinb)*. 2009;19(4):197-200.
4. Kenneth B, Jose AP, Samuel OP, et al. Department of radiological sciences, diagnostic radiology section. University of Puerto Rico Medical Sciences Campus, RSNA, PO Box 5067, San Juan, PR 00936. 2011.
5. Epstein N, Chandran S, Chou L. Current concepts review: intraarticular fractures of the calcaneus. *Foot Ankle Int*. 2012;33(1):79-86.
6. Sanders R, Fortin P, Dipasquale T, et al. Operative treatment in 120 displaced intraarticular calcaneal fractures. Results using a prognostic computed tomography scan classification. *Clin Orthop Relat Res*. 1993;(290):87-95.
7. Berberian W, Sood A, Karanfilian B. CT classification and results of operative treatment. *Foot Ankle Clin*. 2013;55:43-51.
8. Miller MD, Thompson SR. Miller's Review of orthopaedics. 8th ed. Philadelphia, PA: Elsevier, USA; 2019.
9. Brunner A, Heeren N, Albrecht F, et al. Effect of three dimensional three-dimensional reconstructions on reliability. *Foot Ankle Int*. 2012;33(9):727-737.
10. Zhang T, Chen W, Su Y, et al. Does axial view still play an important role in dealing calcaneal fractures? *BMC Surg*. 2015;15(1):19.
11. Vannier MW, Hildebolt CF, Gilula LA, et al. Calcaneal and pelvic fractures; diagnostic evaluation three-dimensional computed tomography scans. *J Digit Imaging*. 1991;4(3):143-52.
12. Madadi F, Moghaddam AS. Diagnostic value of imaging modalities for suspected calcaneal fractures: A systemic review of literature. *Clin Res Foot Ankle*. 2016;87(2):186.
13. Tanyu MO, Vinee P, Wimmer B. Value of 3D CT Imaging in fractures of calcis. *Comput Med Imaging Graph*. 1994;18(3):137-43.